

AN ARGON LASER PHOTOCOAGULATOR

William Liben, B. F. Hochheimer, Arnall Patz

INTRODUCTION

L'ESPERANCE¹ OPENED A NEW DIMENSION IN photocoagulation therapy with the introduction of the argon ion laser as a source of energy. The system developed by L'Esperance was modified and further developed in our laboratories to include both a direct and indirect ophthalmoscopic delivery system. Zweng, Little, and Peabody² and Behrendt³ have constructed argon laser photocoagulation systems and investigated this technique. Argon laser photocoagulators can now be purchased from several manufacturers. This paper describes the instrument developed by the Applied Physics Laboratory - Wilmer Institute cooperative group, reviews the experimental observations in animals, and tabulates the clinical results in the treatment of patients with retinal vascular and macular diseases.

Figure 1 shows schematically the principal

structural features of the eye. The sclera and the cornea form the outer layer of the eyeball; the corneal portion is transparent to allow passage of light into the eyeball. The aqueous humor is a watery mass and is followed by a biconvex lens whose radii can be varied to change the focal length of the eye. The refraction of the light resides in the fixed corneal surfaces and the variable lens surfaces. The iris is a diaphragm whose opening is the pupil, the size of which is varied automatically to compensate for changes in the light intensity. The vitreous humor is a gelatinous mass that provides the necessary spacing for the focusing action to take place. The light is focused on the retina, which contains the photoreceptors that convert the light energy to electrical signals which are transmitted to the brain by the fibers of the optic nerve. Between the retina and the sclera is the choroid, which contains most of the blood vessels that nourish the outer layers of the retina. The disc is a circular area on the retina where the blood vessels and nerve fibers leave the eyeball.

In diabetic retinopathy, now the largest cause of blindness in the United States, the argon laser photocoagulator permits the treatment of abnormal new vessel formations near the optic disc and

Investigation supported by U.S. Public Health Service Research Grant NS-07226 from the National Institute of Neurological Diseases and Stroke.

¹ F. A. L'Esperance, Jr., "An Ophthalmic Argon Laser Photocoagulation System: Design, Construction, and Laboratory Investigations," *Trans. Amer. Ophthal. Soc.* **66**, 1968, 827-904.

² H. C. Zweng, H. L. Little, and R. R. Peabody, *Laser Photocoagulation and Retinal Angiography*, C. V. Mosby Co., St. Louis, 1969.

³ T. Behrendt, "Multiline Argon Laser," *Arch. Ophthal.* **85**, Mar. 1971, 355-358.

An argon laser photocoagulator has been developed and constructed for use in the Wilmer Eye Institute. It has been used with a high degree of success on approximately 400 patients. The principal conditions treated were diabetic retinopathy, macular diseases, and assorted vascular conditions. Delivery of the laser energy to the eye is through either a direct or indirect ophthalmoscope. These instruments were modified to allow simultaneous focusing of the laser energy on the retina and viewing of the retina. The laser light power is variable from one watt to a few milliwatts.

also the treatment of aneurysms and capillary abnormalities in the macular area. Some cases of advanced proliferative diabetic retinopathy that have heretofore been considered untreatable have now been treated successfully.

In the treatment of macular diseases, which account for a large portion of the cases of severe visual impairment in people over fifty years old,

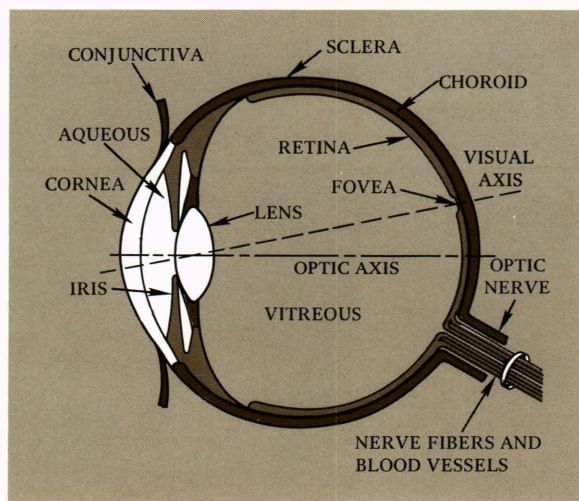


Fig. 1—Principal structural features of the eye.

the ability to place small coagulations has permitted a new approach to this previously untreatable abnormality. These photocoagulations have, in many instances, effectively sealed the pigment epithelium to Bruch's membrane and terminated, or at least arrested, the course of serous detachment in the pigment epithelium. In some cases of hemorrhagic detachment of the pigment epithelium, this treatment has been of value.

The same properties of the argon laser that have made it so useful in diabetic retinopathy have permitted successful treatment of cases of retrolental fibroplasia (abnormal proliferation of retinal vessels leading to scar tissue), sickle cell retinopathy (proliferation of retinal vessels following the occlusion of retinal arterioles), Eales's disease (recurrent retinal or intravitreal hemorrhages in young adults), telangiectasia of the retinal vessels (dilation of the small branch vessels), and neovascularization (formation of new blood vessels) following retinal vein occlusion.

In the two years that the Applied Physics Laboratory-designed instrument has been in use, approximately 400 patients have been treated. These consist of 255 diabetics, 101 patients with macular disease, and the remaining 30 with the assorted vascular conditions just mentioned.

PART ONE

DESIGN AND CONSTRUCTION OF PHOTOCOAGULATOR

Transmission and Absorption of Light in the Eye

The ability of the eye to transmit and absorb light is a factor of basic importance for photocoagulation. Obviously, for the spectral bandwidth of the energy selected for the photocoagulator, the transmission from the cornea to the retina should be large, and its absorption by the portion of the retina treated should also be large.

Losses by reflection at the anterior surface of the cornea are not large and can be computed using Fresnel's laws of reflection. For normal incidence, the reflection loss is about 2.5%, since the index of refraction of the cornea is 1.376. Even at a 45° angle of incidence, the reflection is only 3.4%. At the other interfaces in the eye the reflection losses are very small since the difference in indices is small.

The information necessary for selecting the best spectral region for photocoagulating blood vessels in the retina is shown in Fig. 2. The eye transmission curve gives the relative transmission through the eye to the retina as a function of the wavelength. It is taken from the data of Geeraets and Berry.⁴ The spectral absorption of a 100-micron-thick film of blood is also shown. Its source is L'Esperance.¹ The product of these curves is shown dashed; it is a measure of the fraction of the energy incident on the cornea and absorbed in a retinal blood vessel. Since all of the absorbed energy is converted into heat, the temperature at the absorption site is increased. If this increase is large enough coagulation of the blood will occur.

It appears that the best spectral range for photocoagulation of a blood vessel is from 0.55 to 0.60 micron. Of the commercially available lasers with usefully large power outputs, only the argon CW gas laser appears to be suitable for our purpose. The relative spectral output of the argon gas laser is shown by the vertical lines in Fig. 2. The two principal lines are located at 0.488 and 0.515 micron. Thus, while the argon emission is not of optimum wavelength, it is not far from it.

⁴ W. J. Geeraets and E. R. Berry, "Ocular Spectral Characteristics as Related to Hazards from Lasers and Other Light Sources," *Amer. J. Ophthalm.* 66, Jul. 1968, 15-20.

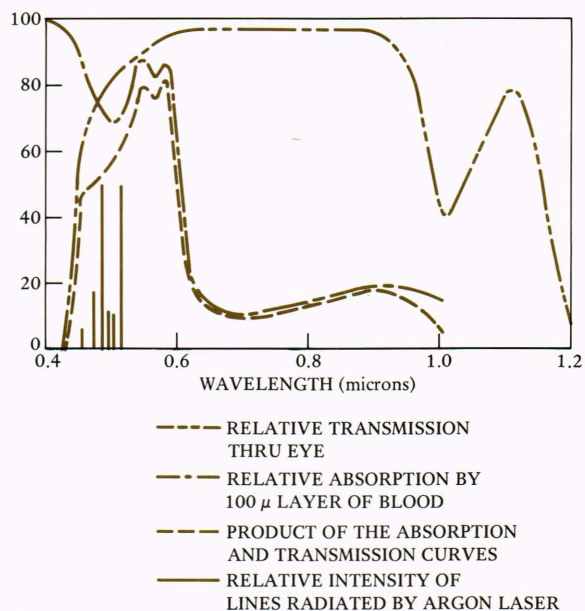


Fig. 2—Spectral transmission of eye, absorption of blood, and emission of argon laser.

Equipment

The photocoagulator as presently constructed is intended to be used with an ophthalmoscope, either direct or indirect, with the patient prone on a stretcher. Figure 3 shows the instrument in use.

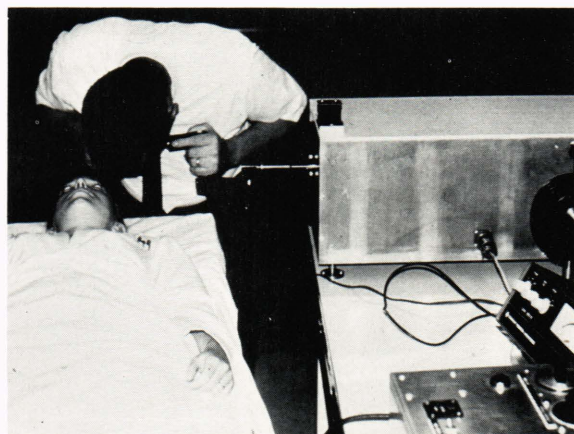


Fig. 3—Photo showing patient prone on stretcher being treated.

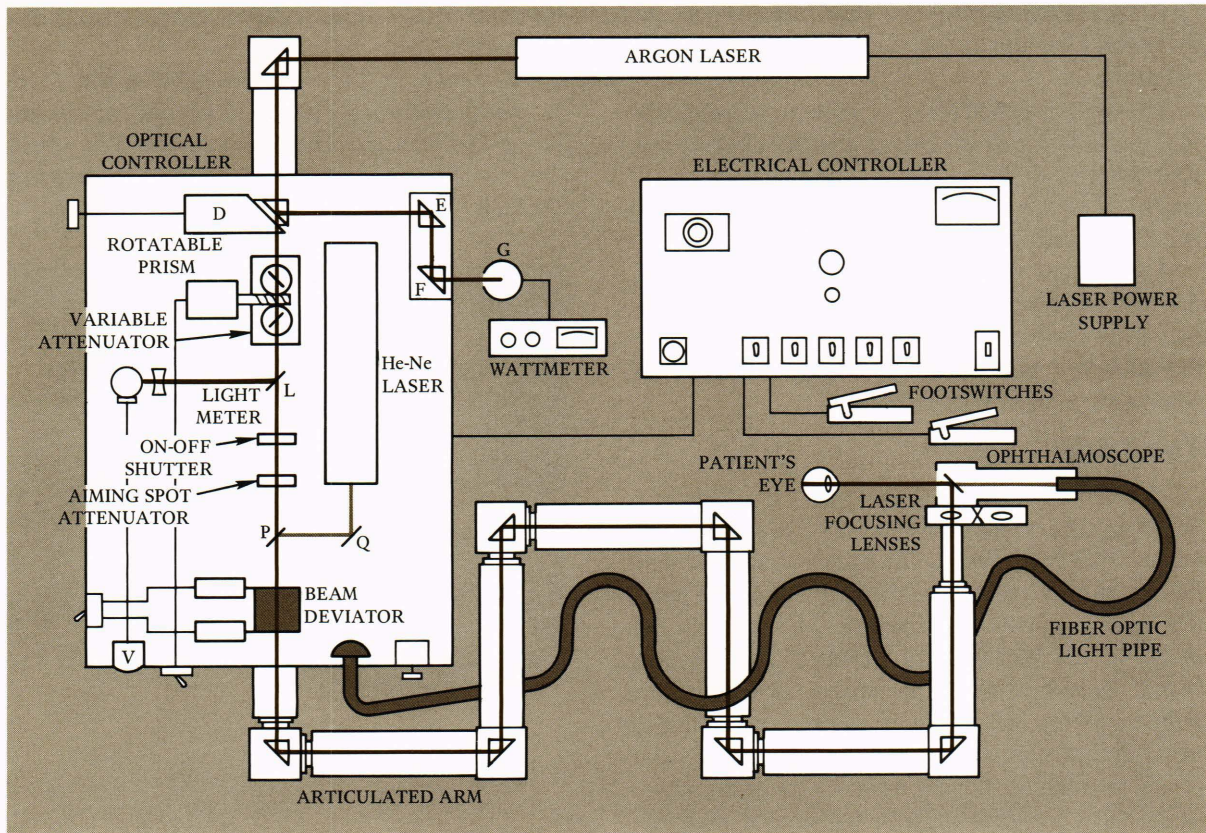


Fig. 4—Schematic of argon laser photocoagulator (Wilmer—APL).

For effective and efficient use the equipment should meet the following requirements.

The physician should be able to:

1. Vary and continuously monitor the laser power output.

2. Have an aiming spot which will permit him to aim or locate the position where the laser beam will strike the retina. The aiming spot should be of low enough power so as not to injure the retina.

3. Align the laser beam to compensate for slight changes in emergence angle from the laser, and for slight changes in the alignment of the prisms in the articulated arm as it is moved.

4. Turn on the beam power for coagulation as required.

5. Retain all of the capabilities of the ophthalmoscope.

6. Focus the laser beam onto the retinal region to be coagulated, whether retinal or intravitreal.

In addition:

1. The laser radiation should not be reflected or scattered into the physician's eye to an appreciable extent.

2. The system should be continuously usable for at least two hours.

3. The spectral range of the light used should be easily transmitted through the eye and essentially all absorbed in the area to be coagulated.

4. The light output of the source should be coherent and collimated.




Fig. 5—Wilmer—APL argon laser photocoagulator.

If these requirements are met, small spots can be imaged on the retina with efficient use of the radiation.

The system constructed is shown schematically in Fig. 4. For convenience it can be divided into four parts: (a) the argon ion laser and its power supply; (b) the optical controller; (c) the electrical controller; and (d) the ophthalmoscope.

The arrangement of the parts is shown in Fig. 5. This arrangement was selected because of the size of the room available and the need to rotate the stretcher with respect to the ophthalmoscope to provide access to either eye.

The Laser

The laser and power supply used is a Coherent Radiation Laboratory Model 52 Argon Ion cw Laser. This is a water-cooled laser with a nominal light output of two watts, divided among the spectral lines as shown in Table 1. The only change made to the unit was to install a key-operated switch in series with the starter switch on the power supply. This was used to prevent accidental or unauthorized laser operation. This laser was found to radiate at least four watts at its maximum rated arc current with reasonable maintenance. The maximum power available at the cornea is one watt.

TABLE 1

NOMINAL LIGHT OUTPUT OF A COHERENT RADIATION LABORATORY MODEL 52 ARGON ION CW LASER

<i>Spectral Line Wavelength (microns)</i>	<i>Power (milliwatts)</i>
0.5145	700
0.5017	150
0.4965	150
0.4880	700
0.4765	250
0.4579	50


The output power can be varied over a range of 7 to 1 by varying the arc current from 30 to 14 amperes. At the low current values the amount of energy in the lines of shorter wavelength exceeds that in the lines of longer wavelength. The laser beam is deflected through 90°, by a right-angle prism, into the optical controller.

The Optical Controller

The parts of the optical controller are assem-

bled into a box; Fig. 6 shows the arrangement of the parts.

As shown in Fig. 4, a rotatable prism D can be positioned to be either in or out of the laser beam. To measure the beam power it is rotated into the beam which then passes through prisms D, E, F, to a laser radiation power meter G.



- | | |
|-----------------------------|---------------------------------|
| 1— WATT-METER | 8— 2.5% TRANSMITTING SHUTTER |
| 2— He-Ne LASER | 9— DICHOIC MIRROR |
| 3— He-Ne LASER REFLECTOR | 10— ON-OFF SHUTTER |
| 4— LIGHT PIPE LAMP | 11— LIGHT SPHERE AND PHOTO CELL |
| 5— VARIABLE AUTOTRANSFORMER | 12— LIGHT METER REFLECTOR |
| 6— BEAM DEVIATOR | 13— VARIABLE ATTENUATOR |
| 7— LASER POWER METER | 14— ROTATING PRISM |

Fig. 6—The optical controller.

With the rotatable prism D out of the optical path, the laser beam passes to a variable attenuator. This device consists of two glass plates, counter-rotatable about vertical axes. Each plate is mounted on a worm gear, both of which are driven by a single worm. The laser beam is polarized with the electric vector vertical; therefore the light transmission at each of the four air-to-glass surfaces is (using one of the Fresnel equations)

$$T = \frac{\sin 2i \sin 2r}{\sin^2 (i + r)}, \text{ and } \sin i = n \sin r,$$

where n is the index of refraction of the glass plates, i the angle of incidence, and r the angle of refraction. The total transmission is given by T^4 because of the four surfaces and is shown plotted versus the angle of incidence in Fig. 7. As presently used, the laser beam power can be varied over a range of 10/1, being limited by the finite beam size. The attenuator is enclosed in a metal

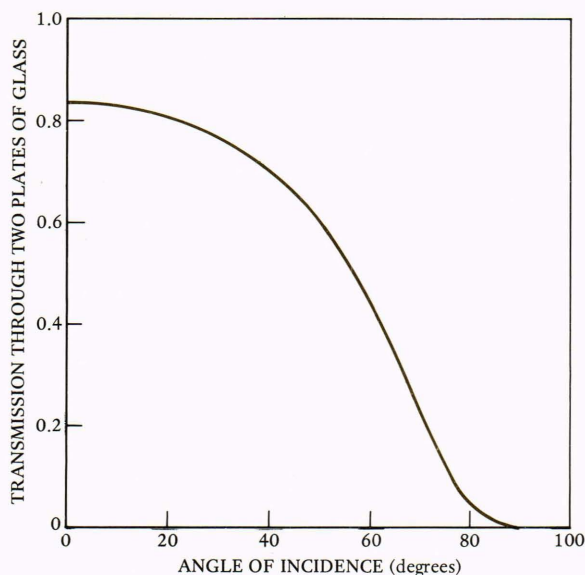


Fig. 7—Transmission through variable attenuator versus angle of incidence ($n = 1.52$).

box to intercept the reflected beams which have sufficient power to damage some of the materials used in the optical controller.

The laser beam then passes through a glass plate L, placed at 45° , where a few percent of the energy is reflected through a negative lens to an integrating sphere and a selenium photovoltaic, photoelectric cell. The output of the photocell is indicated on a meter V. The calibration of this photocell and meter combination is linear. The integrating sphere is made from a translucent ping-pong ball in which a small hole is cut and the photocell is cemented over the hole. The negative lens is used to spread the light over a large area on the ball to prevent burning. The response of this integrating sphere is independent of incidence angle over a few degrees.

The opaque on-off shutter is made of a copper slug that can be raised out of the beam path by a solenoid. This solenoid is actuated by a stepping relay and foot switch located at the electrical controller. Momentary closing of the foot switch will alternately open and close the opaque shutter. This arrangement is particularly useful when it is desired to use the red aiming spot (He-Ne laser) without interference from the argon one. The argon aiming spot attenuator is a partially transparent mirror of $2\frac{1}{2}$ percent transmission which can be raised out of the beam path by actuating a second solenoid. This solenoid is actuated by

closing a foot switch which starts a timer located in the electrical controller. The timer can be preset for 10 to $\frac{1}{30}$ seconds in twenty-four steps. If the foot switch is released before the preset time elapses, the solenoid is deactivated and the $2\frac{1}{2}$ percent attenuator drops into the beam path. This $2\frac{1}{2}$ percent beam is an aiming spot used to locate the laser beam on the retina. This aiming spot is of blue-green light, and as such cannot be seen by the physician, since a Wratten No. 21 filter is used in the ophthalmoscope, but it is actually seen owing to the fluorescence it produces in the retina.

A red aiming spot is often desirable in addition to the green one. This is obtained by using a $\frac{1}{2}$ milliwatt He-Ne laser, reflecting the red beam by a mirror at Q, and superposing it onto the argon laser beam by a dichroic mirror P. The dichroic reflector, made by Liberty Mirror Company as No. 93-700-600, has, at 45° , a high transmission in the blue-green up to 5500 \AA , and a high reflection in the red.

The argon laser beam next passes through a beam deviator. This is a parallel-faced block of glass 23 mm thick that is used to shift the laser beam vertically and horizontally by rotation about horizontal and vertical axes. The rotation is accomplished by two 60 RPM reversible motors geared down with worm gears. For this block of glass the beam deviation is 4.6 mm for a rotation of 30° . Since the beam deviator is used to compensate for angle errors, the ideal beam deviator is a device to vary the laser beam angle. Such a device was used initially; it consisted of two rotatable, $\frac{1}{2}$ diopter optical wedges. However, it was difficult to use since the angle-correcting process was a laborious cut-and-try procedure.

The laser beam passes out of the optical controller into the articulated arm. This device⁵ is used to place and orient the laser beam as needed. The arm consists of six right-angle prisms, each of which is fully rotatable about an axis normal to the prism input face, as shown in Fig. 8. This device gives the beam six degrees of freedom, one each for translation along X, Y, and Z axes, and one each for rotation about the axes.* Output

⁵ F. A. L'Esperance, Jr., E. F. Labuda, and A. M. Johnson, "Photocoagulation Delivery Systems for Continuous-Wave Lasers," *Br. J. Ophthalmol.* **53**, May 1969, 310-322.

* A set of drawings for the articulated arm is available from Bell Telephone Laboratories, Murray Hill, N. J. 07971 (Attention: Jean Dunn). A memorandum describing our experiences with the arm is available from either Dr. Liben or Mr. Hochheimer at the Applied Physics Laboratory.

equipment can be screwed onto the output section. Usually this is a modified ophthalmoscope, but lenses have been used for condensing the energy for iris surgery.

Since a photocoagulation procedure may require an hour or more, the 10 watt lamp usually used in the handle of the ophthalmoscope will raise the handle temperature to an uncomfortably high value, and in addition it is not bright enough due to the modifications made. For that reason the lamp was replaced with a fiber optic light pipe. The input to the light pipe is a tungsten-halogen lamp, Type EJV. It is desirable to operate the lamp at as low a brightness as possible to extend its nominal forty hours of life. This was accomplished by using a variable autotransformer and switching arrangement that only allows the voltage to be applied at a low value and gradually raised to the desired operating value.

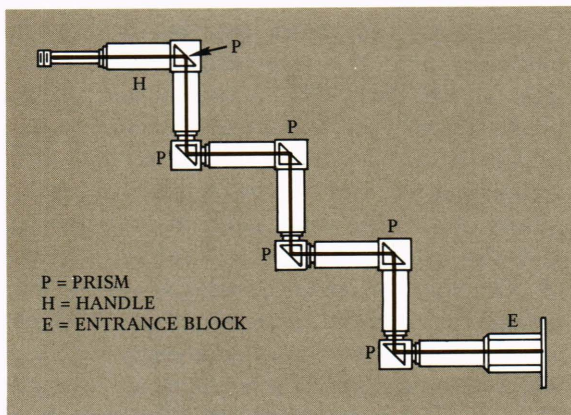


Fig. 8—The articulated arm.

Electrical Controller

The electrical controller shown in Fig. 4 contains all of the remaining electrical circuitry with the exception of the laser power supply. This includes the timer; a time totalizer to count total operating hours of laser; a 3-wire switch to operate room lights; relays; and a voltmeter to monitor line voltage.

Ophthalmoscope

The modifications described here for the ophthalmoscopes are suitable for both the direct and monocular indirect instruments as first described by L'Esperance.




Fig. 9—Reconstructed ophthalmoscope for use on argon photocoagulator.

For the reason already mentioned, the lamp usually used to supply the viewing light located in the handle was replaced by a fiber optic light pipe 48 inches long and $\frac{1}{4}$ inch in diameter. It accepts 70% of the light incident on the end face and has a transmission of 67%. The lamp normally used is mounted in the lower half of the ophthalmoscope handle which is attached to the upper half by a bayonet twist lock. It was convenient to mount the output end of the light pipe in a similar piece also held in place with an identical bayonet twist lock. This modification is shown in Fig. 9.

To protect the ophthalmologist's eye from reflected argon radiation a small square of Wratten 21 filter, in gelatin form, was cemented over the peephole inside the ophthalmoscope. From Fig. 10 we see that the density of this filter for the argon

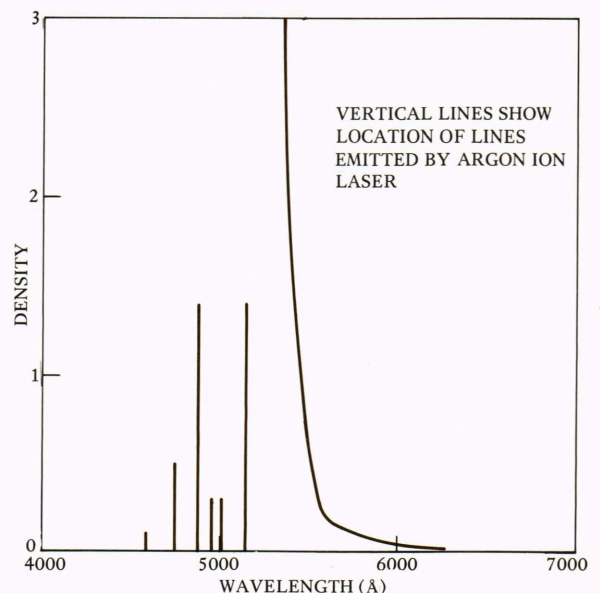


Fig. 10—Density versus wavelength for Wratten 21 filter (Eastman Kodak Co. Data Book B-3).

laser lines is substantially greater than three, so that the transmission is less than 0.1% for the argon radiation.

Since the argon aiming spot is easily seen through this filter, what the observer sees is not argon radiation reflected from the fundus but fluorescence induced by the argon radiation. The He-Ne aiming spot (6328 Å) is easily seen through the Wratten 21 filter.

The ophthalmoscope is attached to the articulated arm via a coupling section shown schematically in Fig. 8. The argon radiation from the articulated arm passes through a lens located in

a rotatable lens wheel visible in Fig. 9. This lens wheel contains sixteen lenses, whose strength increases by steps of one diopter from -8 to +7 diopters, and is used to focus the laser beam onto the retina. The argon radiation is next reflected from a dichroic reflector at 45°. The reflector is in the path of the ophthalmoscope viewing light, so that the argon radiation is superposed onto the viewing light. The dichroic reflector, Liberty Mirror No. 90-480, has good reflection in the green-blue regions of the spectrum and good transmission in the red-orange-yellow regions, when used at 45° incidence.

PART TWO

CLINICAL EXPERIENCE WITH ARGON LASER PHOTOCOAGULATOR

Animal Experiments

The apparatus was tested for safety and reliability using rabbits, cats, and monkeys. Photocoagulation was done simulating the usual clinical methods in each of these three species. In addition, a special experiment was done to test the effectiveness of the argon laser to occlude larger retinal arteries. The results of these studies are briefly summarized as follows.

Areas of the retina were treated by both the application of multiple single spots of coagulation and by the use of a painting technique to cover larger areas of the fundus. The photocoagulation was applied to areas of the retina, avoiding the larger branch retinal vessels and the area of the optic nerve. In the rabbit fundus the lesions were specifically placed to avoid the medullated nerve fibers. The lesions were evaluated in terms of size of area photocoagulated, energy density applied, and duration of photocoagulation. The results confirmed the earlier observation of L'Esperance and demonstrated that the laser caused a significant pigment epithelial and outer retinal coagulation up to and including the inner nuclear layer. When the laser was applied at the accepted standard clinical level of reaction, there was no damage noted in the nerve fiber or ganglion cell layer of the retina. The internal limiting membrane remained intact and showed no evidence of contraction about the areas treated. When an excessive energy level was applied producing a much more severe burn than would be clinically acceptable, the full thickness of the retina was coagulated.

The application of the laser on the retinal arteries at a branch on the optic nerve revealed that they could be brought into severe spasm and totally occluded. In order to permanently stop the retinal circulation it was necessary after the initial photocoagulation of the arteries to then, with a wider beam applied to the retinal veins, stop the exit of blood from the eye. This backing up of blood to the arteries enabled the arterioles to be filled with blood even with an extremely sluggish circulation. Further application of the laser beam on the arteries produced total and permanent occlusion as demonstrated in fluorescein angiography documentation of the retinal circulation and subsequent electroretinography and histologic observations of the treated eyes.

A further test of the argon laser's ability to occlude retinal vessels was done treating the superficial retinal vessels that course along the surface of the medullated nerve fibers in the rabbit. Application of the laser beam to these vessels caused total and complete occlusion of both the arteries and veins. This was significant in that the medullated nerve fibers insulated the underlying pigment epithelium of the rabbit and scattered the energy after it passed into the substance of the retina. The blood in the vessels was apparently the only source of energy absorption.

Clinical Observations

Approximately 400 patients were treated with the argon laser photocoagulator developed by the Applied Physics Laboratory. About two-thirds

were treated with the direct ophthalmoscope delivery and one-third were treated with the monocular indirect delivery system. The indirect unit was found especially useful in treating the retinal periphery and treatment could be effectively performed as far out as the ora using scleral depression. The direct ophthalmoscope was found especially useful in treating new vessels on the optic nerve and in treating lesions about the macula. When an isolated peripheral lesion was treated, no anesthesia was required. However, in the majority of patients a retrobulbar anesthetic was administered.

The clinical use of the instrument can be divided into three major categories: I. Diabetic Retinopathy, II. Macular Disorders, and III. Other Vascular Diseases. Table 2 lists the types of retinal lesion and the number of patients that were treated for each of the retinal diseases.

TABLE 2

PATIENTS TREATED WITH APL-WILMER ARGON LASER PHOTOCOAGULATOR	
<i>I. Diabetic Retinopathy</i>	
Proliferative Retinopathy	187
Background Retinopathy with Macular Edema	68
<i>II. Macular Disorders</i>	
Detachment of Pigment Epithelium	
Hemorrhagic	48
Serous	21
Macular Lipid (Vein Occlusion)	11
Presumed Histoplasmosis	19
Central Serous Detachment of Retina	2
<i>III. Other Vascular Diseases</i>	
Retrolental Fibroplasia	1
Coat's Disease	15
Sickle Cell Retinopathy	6
Eales's Disease	8

I. Diabetic Retinopathy—The two types of diabetic retinopathy treated were (1) proliferative retinopathy and (2) background retinopathy with macular edema.

1. *Proliferative Diabetic Retinopathy.* The photocoagulation of the neovascularization of proliferative diabetic retinopathy can be conveniently discussed in the following categories: (a) surface neovascularization, (b) intravitreal neovascularization, and (c) accompanying microaneurysms and/or intraretinal microvascular abnormalities associated with proliferative diabetic retinopathy.

(a) *Surface Neovascularization*—New surface vessels were treated by placing multiple discrete spots of coagulation or by a painting technique to cover the involved area. The painting strokes were conveniently made to cover a distance of about 1½ disc diameters on the average. Energy level settings were determined in the standard fashion by starting with subthreshold power and gradually building up to a satisfactory white coagulation response in the retina. At this power the blood in the vessels will fragment and the vessels will become obliterated. In treating areas of surface neovascularization where there were large “thin-walled” vessels, care was taken to coagulate the efferent side of the tuft. When finally treating the larger vessels of the tuft, the coagulation spot sizes were made at least 1½ times the width of these vessels to avoid burning a hole in the vessel wall without completely sealing it.

(b) *Intravitreal Neovascularization*

(1) For vessels emanating from the disc or peripapillary zone, the following parameters were evaluated: (a) number of vessels in the vascular frond based on a Grade I to IV classification; (b) plane of proliferation of the new vessels; the elevation, measured in diopters, from the surface of the retina to the anterior tip of the neovascularization was recorded, and the frond elevation was also estimated with the indirect ophthalmoscope and recorded in fractions of a disc diameter elevation; (c) fibrous component of the vascular tuft was graded on a I to IV classification; and (d) fluorescein dye leakage was graded in photographs taken one minute after the initial entrance of fluorescein into the vascular frond was first noted.

Attempts were made to treat the “feeder” vessels to the intravitreal neovascularization. Fluorescein photographs taken in the early transit phase helped identify these feeders in about a third of the cases. Eight-by-ten-inch enlargements of the early transit phase fluorescein photographs placed beside the patient were especially helpful as a guide to therapy.

Where fluorescein did not definitely identify feeder vessels, or in those cases where the fluorescein picture could not be directly extrapolated to the neovascular tuft by direct visualization, usually, but not in all cases, the narrower vessels were observed to be feeders and the larger vessels were on the efferent side of the tuft. Multiple applications of the laser beam were delivered to the

feeder vessels until the blood column fragmented. After treating the feeder vessels in this fashion, if the more peripheral part of the tuft did not fragment its blood column, then a light painting application to the blood in the peripheral complex was applied. Following this, the larger outflow vessels were treated, breaking up the blood column, but being very cautious on these larger vessels to avoid using excessive energy and to be sure that the beam width was at least 1½ times the diameter of the vessel. In large heavy fronds, it was better to divide the treatment into multiple treatments.

(2) For vessels emanating from areas away from the disc, whenever possible, the same principle of locating feeder vessels and treating them before applying the energy to the remainder of the frond was used. In those intravitreal fronds well away from the disc, it was frequently possible to treat the base rather heavily unless one had to straddle one of the major retinal veins.

(c) *Accompanying Microaneurysms and/or Intraretinal Microvascular Abnormalities (IRMA) Associated with Proliferative Diabetic Retinopathy*—Microaneurysms were treated by applying discrete spots of coagulation. When the lesions were near the macula, 50 micron spot sizes were used. Where multiple aneurysms were noted in the periphery, a painting technique was used to eradicate large clusters of aneurysms. IRMA were treated in the same manner as surface neovascularization.

The exact foveal fixation area was determined in patients with microaneurysmal lesions in the immediate macula or paramacula area with a fixation photograph. If visual acuity was less than 20/40, at least three fixation photos were taken to determine the stability of fixation. A Polaroid fixation photograph placed beside the patient served as a useful guide to avoid inadvertent treatment of the fovea.

2. *Background Diabetic Retinopathy with Macular Edema*. Background or intraretinal retinopathy was not treated unless complicated with macular edema. The techniques utilized were those described previously for treatment of microaneurysms and/or intraretinal microvascular abnormalities in the paramacular area. Fluorescein angiography facilitated the identification of major leakage areas. Once treatment was instituted for the paramacular lesions the remaining microan-

eurysms and IRMA scattered throughout the retina were also photocoagulated.

II. **Macular Disorders**—The patients with macular disorders were classified into the following categories: (1) detachment of the pigment epithelium (with or without detachment of overlying sensory retina, hemorrhagic or serous), (2) macular lipid (vein occlusion), (3) presumed histoplasmosis syndrome, and (4) central serous detachment of the sensory retina (central serous choroidopathy or retinopathy).

In performing therapy, the areas of fluorescein leakage demonstrated by photography served as landmarks for the precise placement of photocoagulation. Eight-by-ten-inch enlargements of selected frames of the early and late stages of the fluorescein sequence proved especially useful in selecting the areas to be treated. The following criteria for therapy of macular lesions were applied: (a) a demonstrable leakage of fluorescein, either focal or generalized, (b) absence of advanced cystoid or degenerative changes in the overlying sensory retina, (c) absence of significant fibrous proliferation in the macular area, and (d) reasonable clarity of the media (patients having lens opacification of an equivalent density of 20/80, or poorer, could not be treated satisfactorily with the argon laser).

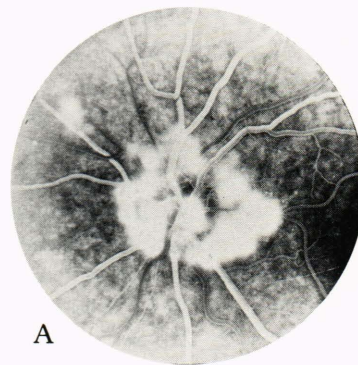
1. *Hemorrhagic and Serous Detachment of Pigment Epithelium*. Where a distinct fluorescein leakage was identified, near but not including the fovea, therapy was confined to the area of leakage. A row of contiguous 50-micron spots was usually placed along the margin nearest the fovea. This served to add another landmark to prevent encroachment on the foveal area and also was helpful in preventing spread of hemorrhage or fluid to the foveal area.

In large pigment epithelial detachments which involved the macula and where no focal fluorescein leakage sites were demonstrated, the following technique was used: a series of 50- to 100-micron spots of coagulation was placed in a horseshoe pattern superior, temporal, and inferior to the macula. Since the patients frequently have eccentric fixation, the nearest spots were placed at least 150 microns from the geographical fovea. Although the macular landmarks were frequently distorted in these cases, approximate localization could be determined by following the course of the paramacular vessels.

Hemorrhagic and serous detachments of the

Patient: H. M., 40 years old, diabetes diagnosed at age 12. Neovascularization emanating from disk, onset diabetic.

- (A) Fluorescein leakage from neovascularization shows heavy staining about the disk.
- (B) Recurrent vitreal hemorrhages have occurred from the neovascularization.
- (C) Immediately after argon laser photocoagulation of neovascularization about the disk.
- (D) Three months after treatment, showing complete eradication of disk neovascularization.

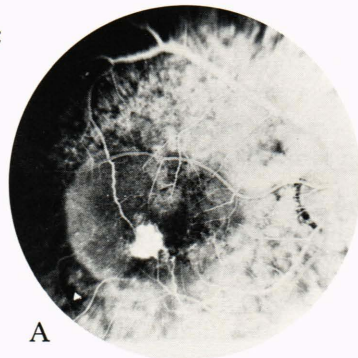


Patient: L. H., 4 month-old infant.

- (B) Early proliferative retrolental fibroplasia with hemorrhages in the vitreous.
- (C) Photograph taken on operating table immediately after application of multiple argon laser photocoagulations in the temporal periphery.
- (D) Areas photocoagulated with argon laser now pigmented and healed. Vitreous has cleared and visual acuity should be normal.

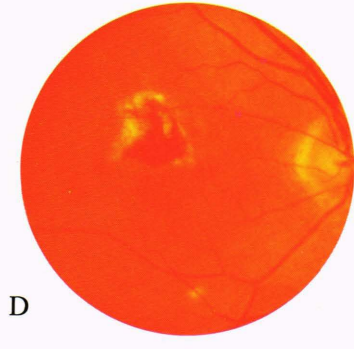
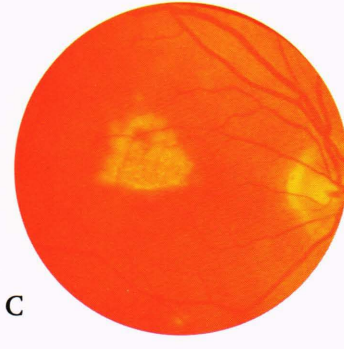
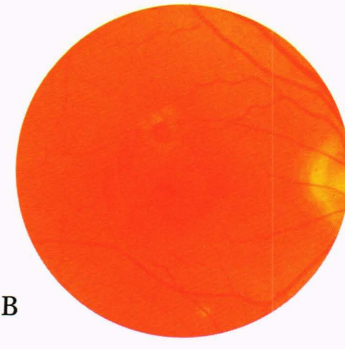
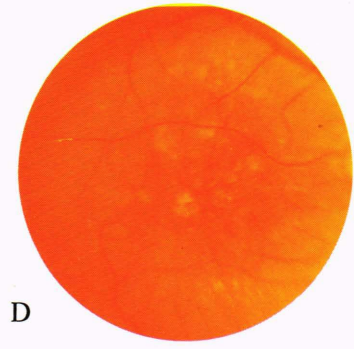
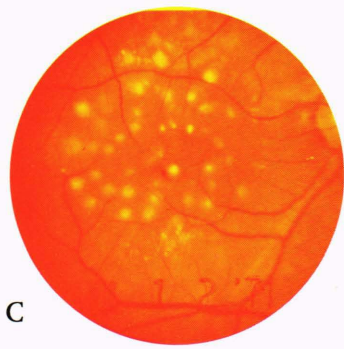
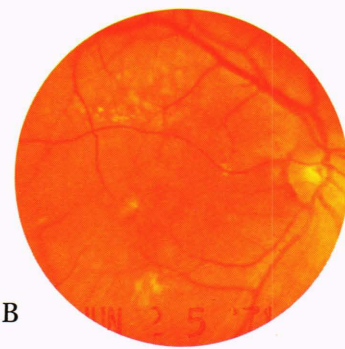
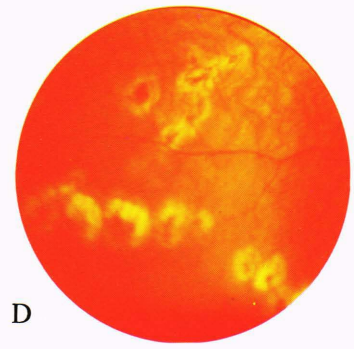
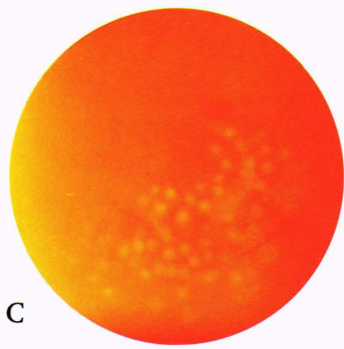
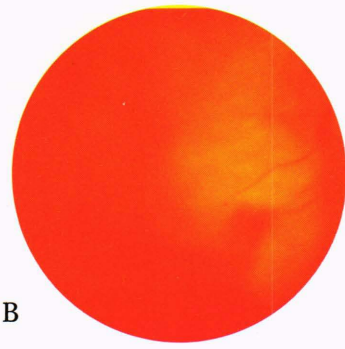
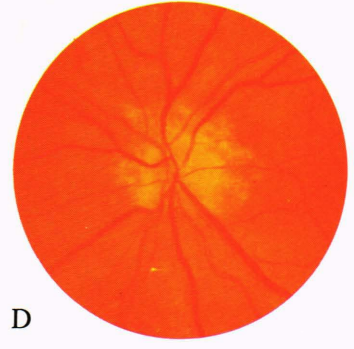
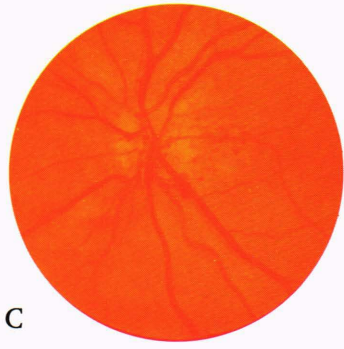
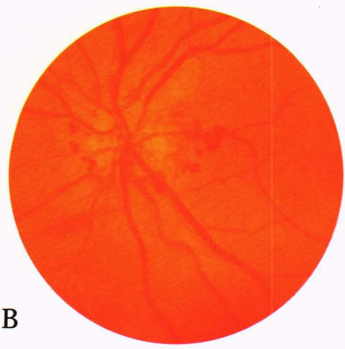
Patient: W. B., 72 year old white male, diabetes of 24-years duration. History of visual impairment of 6 months duration. Vision in right eye 5/200 with glasses.

- (A) Early fluorescein filling of serous detachment of pigment epithelium. Dense staining lesion in center represents fluorescein leakage from retinal microaneurysms.
- (B) Serous detachment of pigment epithelium before treatment.
- (C) Immediately after treatment with the argon laser photocoagulator showing multiple photocoagulation spots scattered throughout the pigment epithelial detachment area.
- (D) Four months after treatment, showing complete flattening of the pigment epithelial detachment. Vision has improved to 20/200.



Patient: R. M., 45 year old white male, visual acuity 20/200.

- (B) Presumed histoplasmosis lesion in the parafoveal area of the right eye.
- (C) Immediately after photocoagulation with the argon laser showing whitening in area treated.
- (D) Six months after therapy showing pigmentation in area treated. The sensory epithelial elevation which involved the macula originally has disappeared. Vision has improved to 20/50.



pigment epithelium were managed by essentially the same technique. The prognosis for patients with hemorrhagic detachment extending into the macular area, however, was much poorer than for similarly located serous detachments.

2. *Retinal Vein Occlusion*. (Followed by macular edema, lipid deposition, and retinal neovascularization.)

3. *Presumed Histoplasmosis Syndrome*. When subretinal neovascularization was demonstrated on fluorescein angiography, the argon laser was used successfully for lesions up to 150 microns from the fovea. When the neovascularization involved the fovea, or extended closer than 150 microns, the argon laser was effective in only one-third of the cases.

4. *Central Serous Detachment of the Sensory Retina* (central serous choroidopathy or retinopathy). When the pigment epithelial defect was located 150 microns or more from the fovea, discrete 50 micron spots of coagulation were applied at these sites.

III. Other Vascular Diseases — Other retinal vascular conditions that have responded favorably to argon laser photocoagulation are the following:

1. *Retrolental Fibroplasia*. Here, the active vascular proliferative stage in the temporal periphery was treated.

2. *Coat's Disease*. This disease, retinal telangiectasis, and Leber's military aneurysms were treated.

3. *Sickle Cell Retinopathy*. Here, the peripheral intravitreal proliferative lesions were treated.

4. *Eales's Disease*. The areas of neovascularization and vascular malformations in the midperiphery along with any neovascularization on the disc were treated.

Clinical Experience

The argon laser coagulator system proved to be extremely helpful in treating intravitreal neovascularization in the periphery, neovascularization about the optic disc, and in the treatment of macular pigment epithelial detachments, either of the serous or hemorrhagic type.

The ability to place photocoagulation spots as small as 50 microns proved particularly useful in photocoagulating lesions up to 150 microns from the fovea. The small spot size of the coagulation also permitted the treatment of new vessels on the disc when they were close to the major retinal vessels.

As with all photocoagulation procedures, opacification of the media impairs the efficiency of photocoagulation. Lenticular nuclear sclerosis (a type of cataract) is a major limitation for the argon laser as the partially opacified lens disperses the radiation. Peripheral cortical spoke opacities of lenses (another kind of cataract) do not seriously impair treatment in the posterior pole but prevent adequate therapy in the periphery. Vitreal opacities, especially vitreal hemorrhages, interfere with adequate coagulation of the retina. We have found that patients with lens opacities which reduce the vision to no less than 20/50 could be adequately treated. Patients with lens opacities of an optical density which reduces the vision to worse than 20/70 are generally not treated.

The major complication of therapy has occurred in the treatment of large intravitreal neovascular tufts. Hemorrhages resulted in about 15% of these cases when a random painting technique was applied to the entire tuft. In those cases where fluorescein studies demonstrated a definite feeder and drainage component pattern of flow in the vascular tuft, the incidence of hemorrhage was reduced significantly by treating the feeder vessels.

The color plate on page 13 shows photographs made on four patients before treatment, immediately after, and a few months after treatment. Where available, fluorescein angiograms are included. The patients were selected to illustrate the effectiveness of the argon laser photocoagulation therapy on four different retinal diseases.

Summary and Conclusions

An argon laser photocoagulator has been developed using a commercial 4-watt argon laser. A delivery system was constructed to permit delivery of the laser energy to the eye through either a direct ophthalmoscope furnishing 15x magnification or an indirect ophthalmoscope furnishing either 3x or 6x magnification. The clinical and experimental studies confirmed and extended the results of L'Esperance. The relatively high absorption of the argon laser radiation by hemoglobin, the high energy density and its precise focusing qualities, make it well suited for the photocoagulation therapy of several retinal vascular and macular diseases. However, further controlled studies are needed to document the beneficial role of this therapy. Opacities of the media were the main obstacles in effective therapy.